

angiography (63%), followed by traditional angiography (24%), was mainly used for diagnosis of these endoleaks. Thirty-nine percent of patients presented with concomitant type II endoleaks. Seventy-six percent of patients were able to have complex endovascular treatment of these endoleaks with a combination of proximal cuff placement (n=44), Aptus Endostaples (n= 6), aorto-unilateral iliac stent grafting (n=19), iliac limb extension (n=35), or complete graft relining (n= 1). Twenty-four percent of patients required open repair with either open plication (n=12) or graft explant (n=21). The median length of stay of patients treated was 8 days (+/- 8). Primary technical success was achieved in 90% of patients with an overall clinical success rate of 78%. The overall complication rate was 44% (66% in patients requiring open aortic surgery) with 18 deaths and an average follow up of 1.75 years.

Conclusions: Endoleaks related to fixation pathology present a complex problem. A totally endovascular treatment algorithm is recommended, with open repair reserved as a last resort. A thoughtful follow up protocol to ensure maintenance of adequate proximal and distal seal zones is recommended through a minimum of 5 years post EVAR.

<http://dx.doi.org/10.1016/j.avsg.2016.10.019>

Contemporary Experience with Open Paravisceral Aneurysm Repair



CrossMark

Mathew D. Wooster, Shivangi Patel, Martin R. Back, and Murray L. Shames

University of South Florida, Division of Vascular Surgery, Tampa, FL.

Introduction and Objectives: To review results of open surgical repair of paravisceral aortic aneurysms in a period dominated by endovascular repair.

Methods: All patients treated by open surgery from January 2010 to March 2015 were identified using billing records. Patients whose aneurysms did not involve visceral vessels were excluded from analysis.

Results: 133 patients with mean 72 years of age were treated during the period, 80.7% of whom were male, with mean aneurysm size 6.5cm(3.5-10cm). Twenty-seven percent of patients treated were non-elective (symptomatic, rupture, or infection). The majority were repaired using tube grafts (55%) and supraceliac clamping (75.2%). Mean procedure time was 224 minutes (120-475 minutes) with a 26-minute (13-45 minute) clamp time, and a 2926mL (550-33,400mL) blood loss. Mortality rate was 9.2% with a minority of surviving patients (35%) requiring extended stay at rehabilitation or nursing facilities prior to return home. Major morbidity consisted primarily of temporary dialysis requirement in 26.2% of patients (1.4% persistent at time of discharge),

with lesser frequency of cardiac abnormalities (13.5%), respiratory complications (23%), wound complications or bleeding (10.5%), and feeding problems requiring PEG placement (7.5%).

Conclusions: Open surgical repair remains a safe option for patients with paravisceral aortic aneurysms; offering acceptable morbidity and mortality rates.

<http://dx.doi.org/10.1016/j.avsg.2016.10.020>

Translating In-Vitro And Computational Multi-Scale Models For The Vascular Surgeon



CrossMark

Benjamin A. Eslahpazir,¹ Kyle W. Beggs,² Zoe M. Lauters,² Alain J. Kassab,² and William M. DeCampi,^{2,3}

¹College of Medicine, University of Central Florida, Orlando, Florida. ²Department of Mechanical and Aerospace Engineering, University of Central Florida, Orlando, Florida.

³Division of Cardiothoracic Surgery, The Heart Center at Arnold Palmer Hospital for Children, Orlando, Florida.

Introduction and Objectives: Hemodynamic modeling of the cardiovascular system has served as an experimental mainstay for over a century yet limited access to contemporary in-vitro and computational models for the vascular surgeon may soon serve as an impediment to progress as the fidelity of these techniques mature. Such models of the human circulation are of variable complexity from zero-dimensions (0D) to three-dimensions (3D) or a combination thereof, otherwise known as the multi-scale model. We have developed an in-vitro multi-scale, pulsatile, patient-specific method for predicting hemodynamic conditions of the vascular anatomy and permits a detailed study of the pressures and flows generated by any multi-vessel region of interest in the human circulatory system.

Methods: Patient-specific vascular anatomy was reconstructed from DICOM CTA images and modified for additive manufacturing with transparent polycarbonate for a 1:1 scale geometry. Vessel-specific input impedance was incorporated at each outlet boundary using 3-element Windkessel constructs to mimic the effects of each respective distal vessel bed. Windkessel air chambers were constructed to recreate vascular compliance and elastic recoil using a specified air volume. Windkessel resistors were constructed using Poiseuille's law for parallel tubes to ensure constant resistance over the cardiac cycle and tuned with Hoffman clamps. Physiological flow was generated using a user-defined waveform programmed into a CPU-controlled servo-motor pump driving a synthetic blood analog created with the Refutas blending equation resulting in a 60:40 water-glycerol solution so as to match normal blood viscosity, further validated by cone-plate viscometry. A programmable

solenoid valve generated paradoxical coronary diastolic perfusion. Flow and pressure measurements at all inlets and outlets were simultaneously recorded.

Results: Average pressure drop across electromagnetic flow sensors measured at 2.44±1.54 mmHg at a flow range of 0-2 L/min for all branch vessels. Synthetic blood viscosity was measured at 4.1 cP, within the normal physiological range. Vascular impedance modulus and phase shift was reproduced within an error of 5% throughout the first two harmonics. Parallel-tube laminar resistors maintained a resistance within 1% of its nominal value up to 1 L/min.

Conclusions: After validating this proof of concept for cardiothoracic applications, we believe this high-fidelity technique lends itself valuable to the close corollary of vascular surgery by generating new data towards today's clinical standards and as a cost-effective, first-line exploratory tool for novel surgical maneuvers.

<http://dx.doi.org/10.1016/j.avsg.2016.10.021>

Minimally Invasive Management Of Renovascular Complications After Renal Graft Transplantation



Francisco J. Gortes,¹ and Jason T. Salsamendi,²

¹Medical Student, University of Miami, Miami, Florida.

²Department of Interventional Radiology, University of Miami, Miami, Florida.

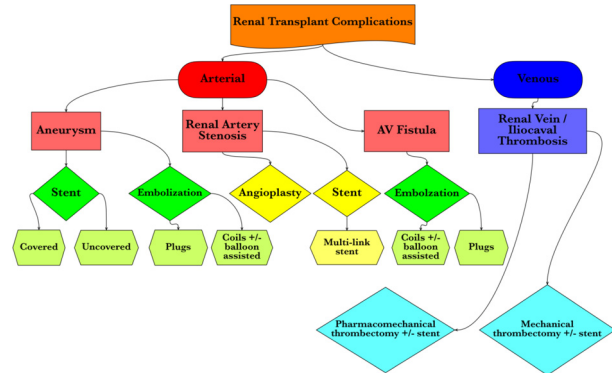
Introduction and Objectives: Renovascular complications after renal transplantation are a significant cause of sudden renal graft loss, occurring in 3-15% of patients. Problems can occur in both the arterial and venous beds. In the arterial bed, potential problems include renal artery stenosis (RAS), which is the most common vascular complication with an incidence of 1-23%, peripheral or central aneurysms (<1%), and renal artery thrombosis (0.5-3.5%). In the venous bed, the major complications are thrombosis of the renal vein (6%), ilio caval system, or both. Arteriovenous fistulas (AVF) may also occur, and span both beds. All of these complications may cause ischemia and subsequent infarction of the renal graft. We aim to educate physicians on the importance of promptly diagnosing and effectively treating early and late onset renovascular complications.

Methods: We present and discuss exemplary cases of RAS, aneurysms, AVF, and ilio caval thrombosis performed at our institution. Steps to reduce iodinated contrast load to the renal graft include CO₂ angiography and intravenous ultrasound (IVUS).

Results: The unique clinical circumstances and anatomical considerations of each patient preclude a universal therapeutic method for any one renovascular pathology. Therefore, we present a flowchart to help

identify the most efficacious therapeutic modalities. We assess the efficacy of endovascular therapies which include angioplasty, stenting, coil embolization, vascular plug embolization, flow-diverting stents, pharmacomechanical thrombectomy (PMT), and mechanical thrombectomy.

Conclusions: Endovascular treatments play a significant role in renal transplant management. Knowledge of available modalities and their application is crucial to minimizing adverse events and improving outcomes.



<http://dx.doi.org/10.1016/j.avsg.2016.10.022>

The Current State of the Vascular Low-Frequency Disease Consortium



Michael P. Harlander-Locke,¹ and Peter F. Lawrence,²

¹Medical Student, Lake Erie College of Osteopathic Medicine, Bradenton, Florida. ²Division of Vascular Surgery, University of California Los Angeles, Los Angeles, California.

Outcomes and management are traditionally best studied through prospective randomized trials or national registries when applicable; however, when clinicians encounter patients with rare vascular pathologies they are often left relying on small-series or case reports in determining the best care. Such vascular anomalies do not go unreported, but due to their rarity it can be difficult for surgeons to conclude what treatment modality provides the least risk and/or best outcomes. To target the shortcoming of contemporary, evidenced-based treatment guidelines, the Vascular Low-Frequency Disease Consortium (VLFDC) was created to examine the management and outcomes of low-frequency vascular diseases using a multi-institutional, standardized, database involving institutions around the United States and globally. The VLFDC has experienced tremendous growth, enrolling more than 2500 patients from 60 institutions over the last 5 years. Using their methods, the VLFDC has completed 6 projects and been able to develop evidenced-based treatment recommendations based on the results. In each study, the VLFDC has been the largest